

Case Report

Correspondence

Kerstin Radike

Radike_K@klinik.uni-wuerzburg.de

Received 24 February 2011

Accepted 18 May 2011

Osteoarticular infection by *Candida albicans* in an infant with cystic fibrosis

Kerstin Radike,¹ Steffen Kunzmann,¹ Marianne Abele-Horn,² Meinrad Beer³ and Helge Hebestreit¹

¹Children's Hospital University of Würzburg, Würzburg, Germany

²Institute for Microbiology, University of Würzburg, Würzburg, Germany

³Pediatric Radiology, University of Würzburg, Würzburg, Germany

Invasive candidiasis is rare in children after the neonatal period, but can occur in children with (secondary) immunodeficiency with a damaged gastrointestinal or skin barrier, or when receiving antibiotics. A 10-month-old girl was diagnosed as suffering from cystic fibrosis (CF) when showing failure to thrive, pulmonary symptoms and hypoproteinaemia. At that time, *Candida albicans* was identified from blood culture and treated intravenously with liposomal amphotericin B for 13 days. Six weeks later, the girl presented with osteoarticular infection of the left knee caused by *C. albicans*. The infection showed insufficient response to therapy with liposomal amphotericin B, but the patient recovered after therapy with fluconazole and flucytosine. Follow-up over 4 years revealed no sequelae. In conclusion, invasive *Candida* infections may occur in patients with CF, and preventive measures might be considered in patients at risk. In the case of an invasive infection, prolonged treatment with a combination of antifungal drugs may be required.

Introduction

Disseminated candidiasis is a major manifestation of opportunistic invasive mycoses. Risk factors include prematurity, central venous catheters, prolonged use of antibiotics, immunodeficiencies, malignancies, malnutrition, steroid use, abnormal skin barriers, gastrointestinal tract defects and surgery. Septic arthritis occurs in 1–2 % of patients with disseminated candidiasis (Pérez-Gómez *et al.*, 1998). Infants younger than 6 months of age comprise 85 % of paediatric cases with fungal arthritis. In children, the knee is the joint involved most often and *Candida albicans* is the fungus isolated in approximately 80 % of cases (Swanson *et al.*, 1996). Seventy to eighty per cent of septic arthritides caused by *Candida* occur in association with osteomyelitis (Lambertus *et al.*, 1988; Swanson *et al.*, 1996).

Despite frequent colonization of the airways in cystic fibrosis (CF) patients by *Candida* and other fungi (Chotirmall *et al.*, 2010), invasive mycoses are rare and, to our knowledge, *Candida* osteoarticular infections have never been described so far in CF. Herein, we present a case of septic osteoarticular infection in a 12-month-old female patient with CF.

Case report

A 10-month-old female infant was admitted with severe failure to thrive, peripheral oedema, pneumonia and hypoproteinaemia (serum protein, 3.7 g dl⁻¹; albumin, 1.9 g dl⁻¹; IgG, 282 mg dl⁻¹). She had a history of recurrent wheezing and multiple respiratory infections. The suspected diagnosis of CF was confirmed by three positive sweat tests and genetic testing ($\Delta F508$ homozygote). Pneumonia was treated with intravenous cefotiam given via a peripheral indwelling catheter, whereon the patient showed clinical improvement (improved oral intake, slower and less shallow breathing). Selection of the antibiotic was based on a throat swab growing standard flora and non-*Haemophilus influenzae* species, but no other bacteria. However, after 9 days antibiotic therapy, the patient developed fever up to 40.6 °C, diarrhoea and elevated white blood cell count (WBC, 38 000 μ l⁻¹), C-reactive protein (CRP, 3.7 mg dl⁻¹) and erythrocyte sedimentation rate (ESR, 91 mm h⁻¹). *Pseudomonas aeruginosa* was detected in stool culture but not respiratory specimens, and antibiotic treatment was changed to ceftazidime and tobramycin. At the same time, mucocutaneous swabs and blood, stool and urine cultures were positive for *Candida albicans*, which was fully susceptible to amphotericin B (MIC, 0.12 μ g ml⁻¹; susceptible if ≤ 1 μ g ml⁻¹), fluconazole (MIC, 0.25 μ g ml⁻¹; susceptible if ≤ 8 μ g ml⁻¹) and flucytosine (MIC, 0.06 μ g ml⁻¹; susceptible if ≤ 4 μ g ml⁻¹), tested by microdilution test following CLSI guidelines M27-A2 and M44-A (NCCLS,

Abbreviations: CF, cystic fibrosis; CRP, C-reactive protein; ESR, erythrocyte sedimentation rate; MRI, magnetic resonance imaging; WBC, white blood cell count.

2002a, b). Intrathoracic and intra-abdominal organ involvement was excluded. The patient was treated with liposomal amphotericin B ($3 \text{ mg kg}^{-1} \text{ day}^{-1}$) and local miconazole, and improved quickly. After 13 days, treatment was discontinued on request of the parents and against medical advice. The patient was discharged in good clinical condition without signs of active infection (normothermia; WBC, $12\,360 \mu\text{l}^{-1}$; CRP, 0.05 mg dl^{-1}).

Six weeks later, the patient presented with fever (39°C) and swelling, warmth and movement restriction of the left knee joint. The patient had no history of trauma and no signs of an upper respiratory tract infection. Laboratory diagnostics showed a WBC of $9\,900 \mu\text{l}^{-1}$, CRP of 2.2 mg dl^{-1} and ESR of 90 mm h^{-1} . Assessment of the joint by ultrasound revealed synovial thickening and an effusion of 5 mm. Magnetic resonance imaging (MRI) showed widespread myositis and osteomyelitis in the distal femoral epiphysis and patella, as well as gonarthrosis (Fig. 1). Arthrocentesis yielded purulent secretion (leukocytes, $3400 \mu\text{l}^{-1}$; neutrophil granulocytes, 91 %) and evidence of *C. albicans* in culture and PCR (fully susceptible to amphotericin B, fluconazole and flucytosine). Cutaneous swabs and stool and blood cultures showed no evidence of *C. albicans*. Further evaluation yielded no additional fungal foci in the cranium, thorax or abdominal organs. Repeated evaluations for congenital immunodeficiency (oxidative burst, lymphocyte subpopulations, immunoglobulin levels including IgG subfractions, vaccination antibodies) were normal.

Treatment for septic osteoarticular infection was started with clindamycin and liposomal amphotericin B ($3 \text{ mg kg}^{-1} \text{ day}^{-1}$). In a follow-up MRI 10 days later, persisting myositis and gonarthrosis were evident. The antifungal therapy was changed to fluconazole ($12 \text{ mg kg}^{-1} \text{ day}^{-1}$) and flucytosine ($100 \text{ mg kg}^{-1} \text{ day}^{-1}$). Clindamycin was stopped after 15 days (cultures were negative for bacteria). After slow clinical improvement over the initial 3 weeks of therapy, MRI showed progressive inflammation (Figs 1 and 2) and the ESR rose from 27 mm h^{-1} 23 days after the start of

treatment to 61 mm h^{-1} 5 days later (WBC, $7\,000 \mu\text{l}^{-1}$; CRP, 3.0 mg dl^{-1}). In consequence, the flucytosine dose was increased ($150 \text{ mg kg}^{-1} \text{ day}^{-1}$) and, since there was some discussion whether staphylococcal disease could be excluded fully, antibiotic therapy with clindamycin was restarted for 22 days. After 6 weeks, intravenous therapy was stopped and oral fluconazole was given for 4 additional months.

At follow-up examinations over 4 years, the girl was physically highly active with no sequelae and no signs of arthritis or movement restriction.

Discussion

Invasive bacterial or fungal diseases are rare in CF. To our knowledge, we describe the first patient with CF presenting with *Candida* osteoarticular infection. Six weeks prior to this infection, the patient had suffered candidaemia possibly facilitated by CF-related malnutrition, hypoproteinaemia with hypothesized secondary immunodeficiency, an indwelling peripheral intravenous catheter, and mucosal candidiasis during intravenous antibiotic therapy. Possibly, some transient immunodeficiency in our patient might also have facilitated the formation of a *Candida* nidus and the initial growth of the fungus in bradytrophic tissues. In our patient, there was no evidence for additional congenital immunodeficiency, which is a main risk factor for invasive candidiasis. There is also no evidence that patients with CF per se have a compromised defence against invasive *Candida* infections.

Guidelines for the treatment of candidaemia available at the time of disease in our patient recommended amphotericin B until complete resolution of signs and symptoms and at least for 14–21 days after the last positive blood culture (Pappas *et al.*, 2004). It is likely that the initial therapy with liposomal amphotericin B for 13 days was too short to be effective. As first-line therapy in *Candida* osteoarticular infections, an initial course of amphotericin B ($3\text{--}5 \text{ mg kg}^{-1} \text{ day}^{-1}$) for 2–3 weeks, followed by fluconazole (6 mg kg^{-1} twice daily) for a total duration of 6–12 months

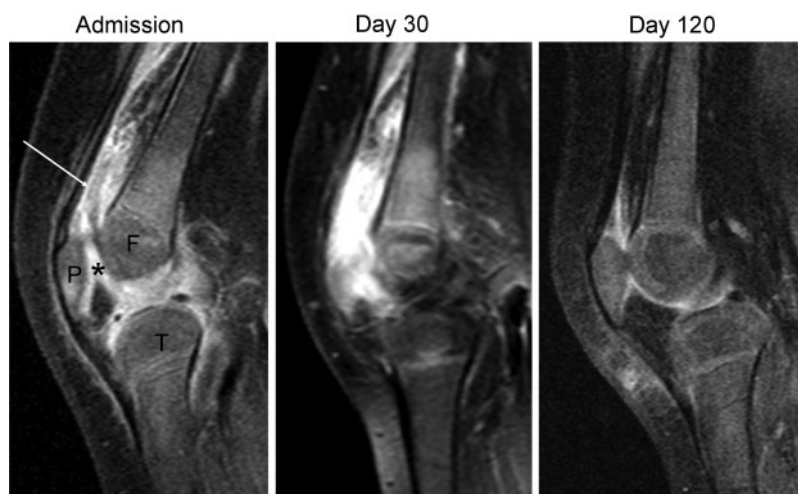


Fig. 1. Sagittal MRI (T1 TSE) of the left knee over time. At baseline, increased contrast uptake of the synovium (asterisk) as well as the bursae (arrow) is seen; during follow-up after an initial increase in disease activity, significant reduction of pathological enhancement at the final control is observed. P, Patella; F, femur; T, tibia.

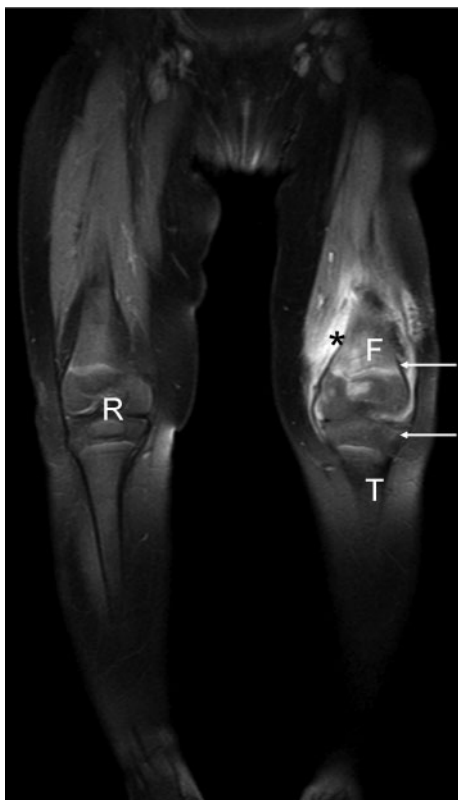

Fig. 2. Coronal MRI (T1 TSE) with contrast medium (gadolinium DTPA) of both lower extremities after 30 days. Compared with the completely normal right knee (R), synovial (asterisk) and osseous (arrows) enhancement of the left knee is seen. F, Femur; T, tibia.

was recommended (Pappas *et al.*, 2004). The more recent guidelines of 2009 for the treatment of candidaemia and *Candida* osteoarticular infections allow starting therapy directly with fluconazole (6 mg kg⁻¹ twice daily) in addition to the older guidelines (Pappas *et al.*, 2004, 2009).

In our case, amphotericin B was clinically not effective despite *in vitro* susceptibility of the isolated *Candida* cells. Therefore, we changed therapy to fluconazole and added flucytosine because low concentrations of fluconazole have been reported in bone by positron emission tomography (Fischman *et al.*, 1993) and synergism has been described (Pérez-Gómez *et al.*, 1998; Rachapalli *et al.*, 2010). Due to the possible malabsorption of oral antifungal agents in patients with CF, we treated intravenously for 6 weeks. Our case indicates that the effect of the recommended antifungal drugs in bradytrophic tissue such as bones and joints might be reduced and that higher doses of drugs or – as employed in our case – additional drugs might be required.

In addition to the antifungal drugs mentioned above, there is growing experience with echinocandins in children. Alternatively to the primary therapy regime, starting therapy with an echinocandin for several weeks followed

by fluconazole for 6–12 months is also recommended in the guidelines (Pappas *et al.*, 2009). For caspofungin, attention should be paid to the importance of dosing based on body surface area rather than weight (50 mg m⁻²). As the available recommendations (Pappas *et al.*, 2004, 2009) are based on limited data mostly from case reports or retrospective studies, further studies are needed.

Differential diagnosis of osteoarticular infections includes idiopathic rheumatoid arthritis and, in CF, CF-related arthropathy, which may also present with pain, swelling, tenderness and limitation of movement of joint as well as fever (Thornton & Rangaraj, 2009).

In conclusion, invasive *Candida* infections may occur in patients with CF and preventive measures should be considered in patients with risk factors such as malnutrition, prolonged antibiotic therapies and/or central venous catheters.

Acknowledgements

The case was presented at the German CF meeting in November 2007.

References

- Chotirmall, S. H., O'Donoghue, E., Bennett, K., Gunaratnam, C., O'Neill, S. J. & McElvaney, N. G. (2010). Sputum *Candida albicans* presages FEV₁ decline and hospital-treated exacerbations in cystic fibrosis. *Chest* **138**, 1186–1195.
- Fischman, A. J., Alpert, N. M., Livni, E., Ray, S., Sinclair, I., Callahan, R. J., Correia, J. A., Webb, D., Strauss, H. W. & Rubin, R. H. (1993). Pharmacokinetics of ¹⁸F-labeled fluconazole in healthy human subjects by positron emission tomography. *Antimicrob Agents Chemother* **37**, 1270–1277.
- Lambertus, M., Thordarson, D. & Goetz, M. B. (1988). Fungal prosthetic arthritis: presentation of two cases and review of the literature. *Rev Infect Dis* **10**, 1038–1043.
- NCCLS (2002a). *Reference Method for Broth Dilution Susceptibility Testing of Yeasts*. NCCLS approved standard M27-A2. Wayne, PA: Clinical and Laboratory Standards Institute.
- NCCLS (2002b). *Reference Method for Antifungal Disk Diffusion Susceptibility Testing of Yeasts*. NCCLS proposed guideline M44-A. Wayne, PA: Clinical and Laboratory Standards Institute.
- Pappas, P. G., Rex, J. H., Sobel, J. D., Filler, S. G., Dismukes, W. E., Walsh, T. J. & Edwards, J. E. (2004). Guidelines for treatment of candidiasis. *Clin Infect Dis* **38**, 161–189.
- Pappas, P. G., Kauffman, C. A., Andes, D., Benjamin, D. K., Jr, Calandra, T. F., Edwards, J. E., Jr, Filler, S. G., Fisher, J. F., Kullberg, B. J. & other authors (2009). Clinical practice guidelines for the management of candidiasis: 2009 update by the Infectious Diseases Society of America. *Clin Infect Dis* **48**, 503–535.
- Pérez-Gómez, A., Prieto, A., Torresano, M., Díez, E., Mulero, J., Labiano, I. & Andreu, J. L. (1998). Role of the new azoles in the treatment of fungal osteoarticular infections. *Semin Arthritis Rheum* **27**, 226–244.
- Rachapalli, S. M., Malaiya, R., Mohd, T. A. & Hughes, R. A. (2010). Successful treatment of *Candida* discitis with 5-flucytosine and fluconazole. *Rheumatol Int* **30**, 1543–1544.

Swanson, H., Hughes, P. A., Messer, S. A., Lepow, M. L. & Pfaller, M. A. (1996). *Candida albicans* arthritis one year after successful treatment of fungemia in a healthy infant. *J Pediatr* **129**, 688–694.

Thornton, J. & Rangaraj, S. (2009). Disease modifying anti-rheumatic drugs in people with cystic fibrosis-related arthritis. *Cochrane Database Syst Rev* (1), CD007336.